

# Stroke

American Stroke  
Association<sup>SM</sup>

JOURNAL OF THE AMERICAN HEART ASSOCIATION

A Division of American  
Heart Association



## **The Utility of Quantitative Magnetic Resonance Angiography in the Assessment of Intracranial In-Stent Stenosis**

Shyam Prabhakaran, Lakshmi Warrior, Kalani R. Wells, Miral D. Jhaveri, Michael Chen and Demetrius K. Lopes

*Stroke* published online Jan 22, 2009;

DOI: 10.1161/STROKEAHA.108.522391

Stroke is published by the American Heart Association, 7272 Greenville Avenue, Dallas, TX 75214  
Copyright © 2009 American Heart Association. All rights reserved. Print ISSN: 0039-2499. Online  
ISSN: 1524-4628

The online version of this article, along with updated information and services, is located on the World Wide Web at:

<http://stroke.ahajournals.org>

Subscriptions: Information about subscribing to Stroke is online at  
<http://stroke.ahajournals.org/subscriptions/>

Permissions: Permissions & Rights Desk, Lippincott Williams & Wilkins, a division of Wolters Kluwer Health, 351 West Camden Street, Baltimore, MD 21202-2436. Phone: 410-528-4050. Fax: 410-528-8550. E-mail:  
[journalpermissions@lww.com](mailto:journalpermissions@lww.com)

Reprints: Information about reprints can be found online at  
<http://www.lww.com/reprints>

# The Utility of Quantitative Magnetic Resonance Angiography in the Assessment of Intracranial In-Stent Stenosis

Shyam Prabhakaran, MD, MS; Lakshmi Warrior, MD; Kalani R. Wells, RN; Miral D. Jhaveri, MD; Michael Chen, MD; Demetrius K. Lopes, MD

**Background and Purpose**—Noninvasive screening for intracranial in-stent stenosis is often limited by artifact because of the stent or associated coils. We aimed to determine the utility of quantitative MRA (QMRA) as a screening tool for detecting intracranial in-stent stenosis.

**Methods**—We reviewed 14 patients who had intracranial stent placement with follow-up QMRA and conventional angiography at our institution. Socio-demographic, medical, clinical, and imaging data were abstracted from medical charts. A blinded interventional neurologist reviewed all angiograms for presence of >50% in-stent stenosis. We tested QMRA (mL/min) at varying thresholds as a predictor of angiographic results.

**Results**—Among 14 patients (mean age, 62 years; 12 female, 2 male), 13 patients had Neuroform stents placed for wide-neck cerebral aneurysms and 1 patient had a Wingspan stent placement for atherosclerotic stenosis. Lesions were located in the intracranial internal carotid artery in 57.2% (n=8), the middle cerebral artery in 14.3% (n=2), and vertebrobasilar arteries in 28.6% (n=4). On follow-up angiography, 2 patients (14.3%) had >50% in-stent stenosis on angiography. Time-of-flight MRA was nondiagnostic in each case because of artifact from the stent or coils. A >20% reduction in vessel-specific blood flow by QMRA was associated with presence of >50% in-stent stenosis on angiography ( $P=0.033$ ). As a screening tool to predict >50% angiographic in-stent stenosis, the sensitivity, specificity, positive predictive value, and negative predictive value of QMRA were 100%, 92%, 67%, and 100%, respectively.

**Conclusion**—We found that QMRA is a promising screening tool to detect intracranial in-stent stenosis. Future prospective studies should focus on whether QMRA has a role in the detection of radiographic restenosis and prediction of clinical events. (*Stroke*. 2009;40:00-00.)

**Key Words:** blood flow ■ NOVA ■ screening ■ sensitivity

In-stent stenosis or thrombosis is not an infrequent complication after intracranial stent placement.<sup>1,2</sup> Because noninvasive imaging such as magnetic resonance angiography (MRA) and computerized tomography angiography are often degraded by artifact caused by the stent itself or associated coils, digital subtraction angiography (DSA) continues to be utilized routinely after stent placement. DSA, however, carries a 1% risk of neurological and non-neurological procedural complications.<sup>3</sup> Thus, the development of a reliable noninvasive screening test would help reduce these risks and provide accurate detection of in-stent stenosis in this high-risk patient population.

Quantitative MRA (QMRA) uses traditional time-of-flight and phase-contrast MRI to visualize vascular anatomy and measure blood flow.<sup>4</sup> Recent studies have established this technology's utility in the measurement of arterial blood flow in various cerebrovascular conditions such as vertebrobasilar

insufficiency and carotid bypass surgery.<sup>5,6</sup> A recent report also found it was useful in assessing blood flow after extracranial vertebral artery Wingspan stent placement.<sup>7</sup>

However, there are no studies of QMRA in the detection of intracranial in-stent stenosis. In a single-center retrospective study, we postulated that angiographic in-stent stenosis could be detected noninvasively with QMRA.

## Materials and Methods

We conducted a retrospective review to identify all patients who met the following inclusion criteria: (1) stent placement for cerebral aneurysm or intracranial stenosis; (2) QMRA scan performed within 1 year after stent placement; (3) follow-up diagnostic angiography study performed within 1 month of the QMRA scan; and (4) high-quality QMRA images without motion artifact.

Fourteen patients met these criteria. Socio-demographic, medical, clinical, and imaging data were abstracted from medical charts. A blinded neuroradiologist (M.D.J.) reviewed the QMRA data and a

Received April 5, 2008; final revision received May 23, 2008; accepted June 11, 2008.

From Department of Neurological Sciences (S.P., L.W., M.C.), Neurosurgery (K.R.W., D.K.L.), and Radiology (M.D.J.), Rush University Medical Center, Chicago, Ill.

Correspondence to Shyam Prabhakaran, MD, MS, Rush University Medical Center, 1725 W. Harrison Street, Suite 1121 Chicago, IL 60612. E-mail shyam\_prabhakaran@rush.edu

© 2009 American Heart Association, Inc.

Stroke is available at <http://stroke.ahajournals.org>

DOI: 10.1161/STROKEAHA.108.522391

**Table 1. Characteristics, QMRA, and Angiographic Findings in the Cohort (N=14)**

	Stent Location (Type)	QMRA Vessel	QMRA Flow (Normal Range in mL/min)	QMRA*	DSA†
1	Right MCA (Neuroform)	Distal right MCA	43 (100–200)	+	+
2	Basilar artery (Neuroform)	distal basilar artery	179 (160–260)	–	–
3	Left supraclinoid ICA (Neuroform)	Left ACA and MCA	ACA 92 (60–170) MCA 103 (110–210)	–	–
4	Right supraclinoid ICA (Neuroform)	Right ACA and MCA	ACA 71 (60–160) MCA 143 (100–200)	–	–
5	Left supraclinoid ICA (Neuroform)	Left ACA and LMCA	ACA 96 (60–170) MCA 183 (110–210)	–	–
6	Right vertebral artery (Neuroform)	Distal right vertebral artery	212 (80–170)	–	–
7	Right supraclinoid ICA (Neuroform)	Right MCA (right ACA hypoplastic)	86 (100–200)	–	–
8	Right supraclinoid ICA (Neuroform)	Right MCA (right ACA hypoplastic)	151 (100–200)	–	–
9	Right supraclinoid ICA (Neuroform)	Right ACA and MCA	ACA 100 (60–160) MCA 103 (100–200)	–	–
10	Left vertebral-basilar junction (Wingspan)	Proximal basilar artery	31 (160–260)	+	+
11	Left supraclinoid ICA (Neuroform)	Left ACA and MCA	ACA 55 (60–170) MCA 85 (110–210)	–	–
12	Right supraclinoid ICA (Neuroform)	Right ACA and MCA	ACA 167 (60–160) MCA 240 (100–200)	–	–
13	Basilar artery (Neuroform)	Distal basilar artery	161 (160–260)	–	–
14	Left MCA (Neuroform)	Distal left MCA	61 (110–210)	+	–

\*+ represents >20% reduction in vessel-specific flow by QMRA.

†+ represents >50% stenosis by angiography.

ACA indicates anterior cerebral artery; MCA, middle cerebral artery.

blinded interventional neurologist (M.C.) reviewed angiograms for >50% in-stent stenosis. Noninvasive optimal vessel analysis (NOVA; Vassol, Inc) was performed as follows: using routine 3-dimensional time-of-flight MRA, the vessel segment distal to the stent was identified and a slice placed perpendicular to the vessel axis; volumetric flow rate was obtained using cine phase contrast MRI and compared to published data from controls.<sup>4,5</sup> We assessed 2 cutoffs to define “low flow” by QMRA (>15% and >20% reduced flow). The Fisher exact test was used to determine the association between the 2 cutoffs for “low flow” by QMRA and >50% stenosis by DSA. Significance was set at  $P<0.05$ . We calculated the specificity, sensitivity, and positive and negative predictive values of QMRA for both cutoffs. Statistical analyses were performed using SPSS 14.0.

## Results

Median age of the cohort was 59.5 years and 12 were female. Thirteen patients had Neuroform stents placed for wide-neck cerebral aneurysms and 1 patient had a Wingspan stent placement for atherosclerotic stenosis. Lesions were located in the intracranial internal carotid artery in 57.2% ( $n=8$ ), the middle cerebral artery in 14.3% ( $n=2$ ), and vertebrobasilar arteries in 28.6% ( $n=4$ ). Table 1 summarizes results of QMRA and DSA in each patient.

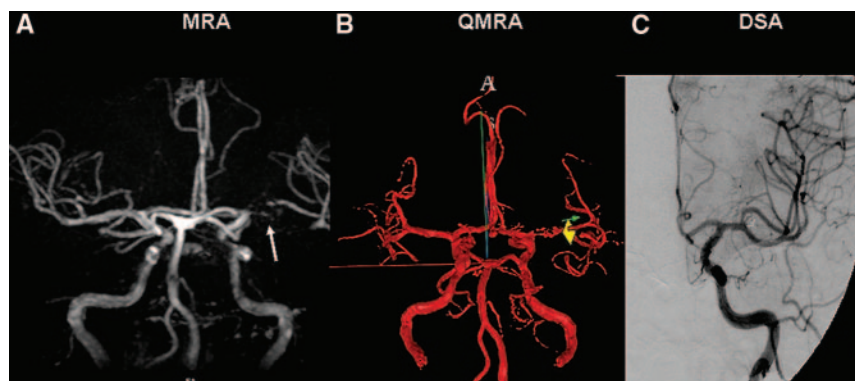
The median time from stent to follow-up QMRA was 192 days (interquartile range, 151–215 days). The median time

between follow-up angiography and QMRA was 0.5 days (interquartile range, 0–11 days, with 6 completed on the same day). On follow-up diagnostic DSA, 2 patients (14.3%) had >50% in-stent stenosis. Time of flight MRA was nondiagnostic in each case because of artifact from the stent or coils (Figure). A >15% decrease in QMRA vessel flow was not significantly associated with >50% in-stent stenosis ( $P=0.110$ ). However, presence of >20% reduction in QMRA vessel flow was significantly associated with stenosis by DSA ( $P=0.033$ ).

Using the threshold of 15% decrease in vessel flow, sensitivity of QMRA to detect >50% angiographic in-stent stenosis was 100%, with a specificity of 75%; the positive predictive value was 40% and negative predictive value was 100%. Using the threshold of 20% decrease in vessel flow, the sensitivity and negative predictive value remained 100%, whereas specificity and positive predictive value increased to 92% and 67%, respectively (Table 2).

## Discussion

We found that low blood flow as measured by QMRA at sites of intracranial stent placement was significantly associated with in-stent stenosis by catheter-based angiography. Using



**Figure.** Patient with left middle cerebral artery stent. A, MRA with characteristic artifact around stent. B, QMRA with flow measured immediately distal to stent. C, DSA showing patency of stent.

**Table 2. Association Between QMRA Results and Follow-Up DSA Results**

QMRA Vessel-Specific Flow	>50 % Angiographic Stenosis		P	Sensitivity (%)	Specificity (%)	PPV (%)	NPV (%)
	Yes	No					
<b>&gt;15% reduction</b>							
Yes	2	3	0.110	100	75	40	100
No	0	9					
<b>&gt;20% reduction</b>							
Yes	2	1	0.033	100	92	67	100
No	0	11					

NPV indicates negative predictive value; PPV, positive predictive value.

the 20% decrease in QMRA vessel flow, the sensitivity, specificity, and negative predictive value were excellent whereas the positive predictive value was fair. Given the potential clinical consequences of in-stent stenosis, a test with a high sensitivity and an acceptably low false-positive rate (33%) are desirable. In addition to identifying all true cases of in-stent stenosis, the high negative predictive value of the test might be used to defer follow-up DSA in those with normal QMRA results.

The limitations of this study include its small sample size and its retrospective nature. Our findings, therefore, require confirmation in larger prospective studies. Although contrast-enhanced MRA and computerized tomography angiography provide some anatomic visualization at sites of stent placement,<sup>8,9</sup> QMRA has the advantage of also providing physiological data. However, the best value that defines abnormality by QMRA is yet to be determined. Comparing absolute or relative reductions to normative data are one approach, whereas intraindividual change over time may be another useful approach. An intraindividual ratio of vessel blood flow to total cranial flow may be the best measure in diseased states and allow adjustment for confounding factors such as hypotension or congestive heart failure and measurement of regional or collateral blood flow.<sup>4</sup> We were unable to calculate this ratio for all patients because of incomplete measurements for all cranial arteries.

### Conclusion

We found that QMRA is a promising screening test to detect intracranial in-stent stenosis with high sensitivity and specificity. Further prospective study is warranted.

### Disclosures

Dr Lopes owns shares in and is on the advisory board for Vassol, Inc.

### References

1. Fiorella D, Albuquerque FC, Woo H, Rasmussen PA, Masaryk TJ, McDougall CG. Neuroform in-stent stenosis: Incidence, natural history, and treatment strategies. *Neurosurgery*. 2006;59:34–42.
2. Levy EI, Turk AS, Albuquerque FC, Niemann DB, Aagaard-Kienitz B, Pride L, Purdy P, Welch B, Woo H, Rasmussen PA, Hopkins LN, Masaryk TJ, McDougall CG, Fiorella DJ. Wingspan in-stent restenosis and thrombosis: Incidence, clinical presentation, and management. *Neurosurgery*. 2007;61:644–650.
3. Dawkins AA, Evans AL, Wattam J, Romanowski CA, Connolly DJ, Hodgson TJ, Coley SC. Complications of cerebral angiography: A prospective analysis of 2,924 consecutive procedures. *Neuroradiology*. 2007;49:753–759.
4. Zhao M, Amin-Hanjani S, Ruland S, Curcio AP, Ostergren L, Charbel FT. Regional cerebral blood flow using quantitative MR angiography. *AJNR Am J Neuroradiol*. 2007;28:1470–1473.
5. Amin-Hanjani S, Du X, Zhao M, Walsh K, Malisch TW, Charbel FT. Use of quantitative magnetic resonance angiography to stratify stroke risk in symptomatic vertebrobasilar disease. *Stroke*. 2005;36:1140–1145.
6. Amin-Hanjani S, Shin JH, Zhao M, Du X, Charbel FT. Evaluation of extracranial-intracranial bypass using quantitative magnetic resonance angiography. *J Neurosurg*. 2007;106:291–298.
7. Brisman JL. Wingspan stenting of symptomatic extracranial vertebral artery stenosis and perioperative evaluation using quantitative magnetic resonance angiography: Report of two cases. *Neurosurg Focus*. 2008;24:E14.
8. Lovblad KO, Yilmaz H, Chouiter A, San Millan Ruiz D, Abdo G, Bijlenga P, de Tribolet N, Ruefenacht DA. Intracranial aneurysm stenting: Follow-up with MR angiography. *J Magn Reson Imaging*. 2006;24:418–422.
9. Turk AS, Rowley HA, Niemann DB, Fiorella D, Aagaard-Kienitz B, Pulfer K, Strother CM. CT angiographic appearance of in-stent restenosis of intracranial arteries treated with the Wingspan stent. *AJNR Am J Neuroradiol*. 2007;28:1752–1754.